

Infectious lameness among migratory sheep and goats in north-west India, with particular focus on anaerobes

A.H. Wani ⁽¹⁾, S. Verma ^{(1)*}, M. Sharma ⁽¹⁾ & S.A. Wani ⁽²⁾

(1) Department of Veterinary Microbiology, Dr. G.C. Negi College of Veterinary and Animal Sciences, CSKHPKV, Palampur, Himachal Pradesh-176062, India

(2) Division of Veterinary Microbiology and Immunology, SKUAST-K, Shuhama (Alusteng) Campus, Srinagar, Jammu and Kashmir-190006, India

*Corresponding author: sverma8@gmail.com

Summary

Various bacterial species, particularly *Dichelobacter nodosus*, *Fusobacterium necrophorum*, *Trueperella pyogenes* (previously *Arcanobacterium pyogenes*) and *Treponema* spp., have been implicated in infectious conditions manifesting in lameness in sheep and goat populations. The current study reports the causes of infectious lameness in the north-western Himalayan region, particularly Himachal Pradesh (HP), where no such study has been conducted in the past. Among a total surveyed population of 27,586 animals, comprised of 15,006 sheep and 12,580 goats, 216 samples were collected from foot lesions. A total of 6.48% (14/216) samples were positive for *D. nodosus*, 20.83% (45/216) for *F. necrophorum* and 20.37% (44/216) for *T. pyogenes*. In three instances, all of the three aforementioned bacteria were present in a single foot lesion. Most of the positive samples were from areas in the state of HP adjoining the state of Jammu and Kashmir (J&K), where footrot is endemic. The confirmation of footrot in HP and the fact that *F. necrophorum* and *T. pyogenes* were detected from cases of foot/hoof infection in high numbers emphasises that these organisms play an important role in inducing morbidity in migratory sheep and goats. The present investigation also confirms the detection of *D. nodosus* from cases of footrot for the first time from HP. With new reports identifying *F. necrophorum* as a pathogen with a potential role in aggravating infection caused by footrot, the development of a combined vaccine to prevent lameness in sheep and goats in the north-western Himalayan region has been suggested.

Keywords

Anaerobes – *Dichelobacter nodosus* – Foot abscess – Footrot – *Fusobacterium necrophorum* – Goat – Infectious lameness – Sheep – *Trueperella pyogenes*.

Introduction

Lameness is one of the greatest concerns for poor welfare in sheep (1). Economic losses to the sheep and goat rearing industry due to lameness are considerable. Lameness caused by footrot has been estimated to cost the United Kingdom (UK) sheep and goat industry around £24 million (US\$25.9 million) per annum (2) with an additional burden of £14 million (US\$15.1 million) annually for the

prevention of the disease (3). New South Wales experiences an estimated AU\$43 million (US\$33.4 million) loss per annum in terms of losses in production, treatment, control, prevention and eradication of footrot (4).

Lameness in sheep and goats due to involvement of the feet is often due to an infectious aetiology. Various bacterial species, particularly *Dichelobacter nodosus* (5), *Fusobacterium necrophorum* (5), *Trueperella pyogenes* (6) and *Treponema* spp. (7), have been associated with lameness. Viral diseases

such as foot and mouth disease and bluetongue also affect the feet of animals but the lesions are not restricted to the feet only (8). Conditions such as interdigital dermatitis (ID) (also known as scald) and virulent footrot (VFR), involving *D. nodosus* as a primary pathogen, account for about 90% of lameness in sheep in the UK (9). Other conditions causing foot lameness include contagious ovine digital dermatitis, foot abscesses, shelly hoof and toe granulomas (10).

Until recently the pathogenesis of footrot was thought to be due to an initial infection by *F. necrophorum* followed by a secondary infection with *D. nodosus* (11), but recent studies suggest otherwise. Regardless, both bacteria play an important role in footrot infection, with *D. nodosus* possibly driving the pathogenesis of footrot from the initiation of interdigital dermatitis through to the development of severe footrot, and *F. necrophorum* likely attributing to the severity and duration of the infection (12, 13). In cases of foot abscesses, *F. necrophorum* has been associated in conjunction with *T. pyogenes* (8, 14).

Around 65% of the total population of India depends directly on agriculture and allied activities for their livelihood and employment, which accounts for around 22% of the gross domestic product (GDP). The livestock sector represents approximately 27% of this amount. The most recent census conducted in 2007 showed that there were 71.6 million sheep and 140.5 million goats in India, making these industries an important component of the livestock sector (15).

The state of Himachal Pradesh (HP), which is home to the highest section of the Himalayan mountain ranges (the Great Himalayas), is situated in the north region of India and has a considerable population of sheep and goats. According to the census conducted by the Department of Animal Husbandry in HP (2007), the total population of livestock in this state is estimated to be 5,211,087 of which 901,540 are sheep and 1,240,835 are goats (16).

In India there are several published reports (17, 18, 19, 20, 21) that highlight the incidence of footrot in sheep and goats in the neighbouring state of Jammu and Kashmir (J&K), especially in the Kashmir division. In the state of J&K, losses in sheep production as a result of footrot were estimated around Rs 36.79 million (US\$0.56 million) (20) and Rs 15.82 million (US\$0.25 million) (21) per annum in south Kashmir and central Kashmir, respectively. Footrot has also been reported from the south Indian states of Andhra Pradesh (22) and Kerala (23). The climatic conditions and animal husbandry practices in HP and Uttarakhand, another northern state, are very similar to those in J&K. With the expanding tracts of migration and mixing of sheep and goat flocks in common grazing pastures at the borders, the sheep and goat-rearing communities of HP remain highly vulnerable to severe economic losses due to infectious

lameness. With this background a study was undertaken to ascertain the status of disease conditions of the foot in sheep and goats in this Himalayan state.

Materials and methods

Survey area

The study was conducted from March 2010 to May 2011. During this period various areas and villages which fall *en route* to the highland pastures, where a considerable population of sheep and goats are present, were surveyed. The areas included seven districts in HP, i.e. the district of Lahaul and Spiti and the districts of Chamba, Kullu, Kangra, Hamirpur, Mandi and Una, and one district in J&K, i.e. Kishtwar district (previously part of the Doda district). No such study had been undertaken in these areas before (Fig. 1). Three sheep breeding farms in HP, which had never been investigated for conditions associated with foot lameness, were also visited to determine the prevalence of footrot infection. The animals on the farms were stall-fed and the adjoining land served as a grazing and exercising area. These areas often become water logged in the monsoon months, thus creating a favourable environment for the propagation of footrot and other hoof infections.

Sample collection

Two forms of symptomatic lameness were observed in the sheep and goats. Examination of these animals revealed lesions that resembled footrot or lesions that were indistinguishable from foot abscesses. In the case of animals showing lesions similar to footrot, the site sampled was the active lesion that developed between the horn of the hoof and the sensitive underlying tissues. In cases of lameness due to an abscess, the pus oozing out of the hooves from the coronary band or the white (or somewhat paler) line just above the hooves and interdigital space was sampled.

Altogether, 104 flocks and three sheep breeding farms were visited. A total of 216 samples were collected from 2,753 animals, which comprised 134 samples from sheep and 82 samples from goats. Most of the flocks (90/104) were a mix of sheep and goats.

Lesions resembling footrot with a lesion score of 2 (interdigital dermatitis) (Fig. 2a) to 4 (under-running of the horn of the hoof) (Fig. 2b) (24) and exudates of foot abscesses, i.e. green-creamy pus oozing out from the coronary band or from pus of the interdigital space (Fig. 2c), were sampled from deep inside the lesions with sterilised cotton swabs. The samples were collected in duplicate from each site; one was used for isolation of *D. nodosus* and direct DNA extraction and the other for the isolation of aerobic bacteria. The swab used for the isolation of *D. nodosus*

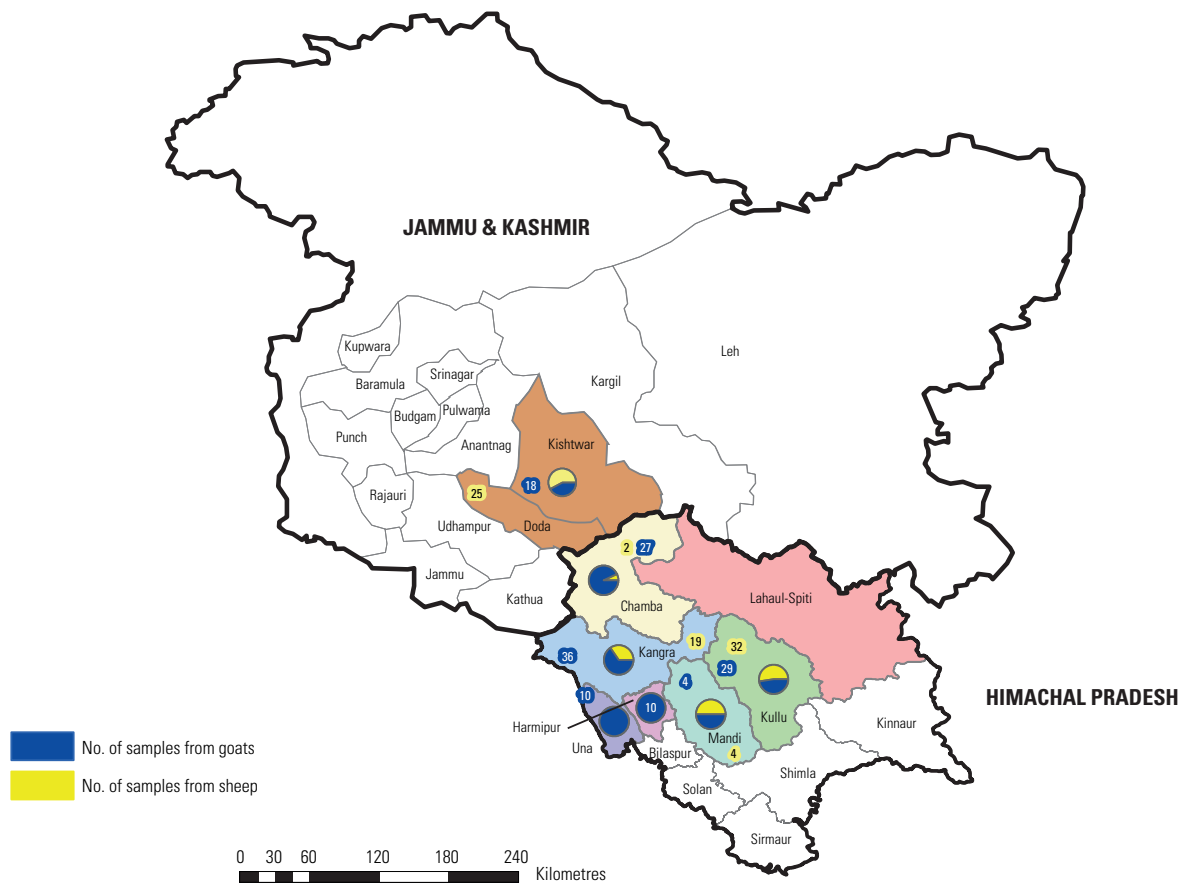


Fig. 1
Distribution of samples by species in Himachal Pradesh and the district of Kishtwar (previously part of the district of Doda) in Jammu & Kashmir

Source: Centre for Geo-informatics, CSK Himachal Pradesh Agricultural University

was first streaked on isolation medium on site and then stored in 200 µl of sterile phosphate-buffered saline (PBS) in a sterilised microcentrifuge tube. The duplicate swabs were transported to the laboratory on ice. On reaching the laboratory, microcentrifuge tubes with samples meant for direct detection were stored at -20°C until further use. The duplicate swabs were processed aerobically. Among the anaerobic bacterial species, only isolation of *D. nodosus* was attempted as it was reported to be the major cause of lameness in the neighbouring state of J&K (17, 18, 19, 20, 21); *F. necrophorum* and *T. pyogenes* (microaerophilic) detection was performed by polymerase chain reaction (PCR).

Random examination of sheep and goats not showing any apparent symptoms of lameness was also carried out. Upon examination, those animals that had lesions were also sampled to establish the infectious aetiology. Twenty samples from asymptomatic animals (8 from sheep and 12 from goats) were collected and were included as part of the total 216 samples processed in this study.

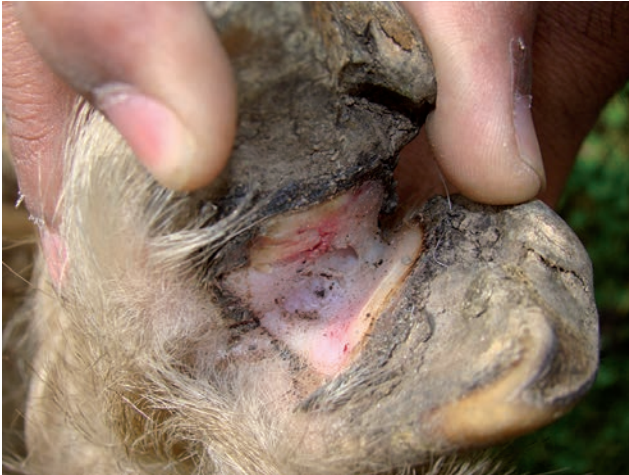DNA Extraction

DNA extraction from direct swabs was performed by vortexing the microcentrifuge tubes containing the swabs for 5 min. After vortexing, the swabs were removed from the microcentrifuge tubes. The suspension was then heated to 98°C for 5 min, cooled on ice for 10 min and centrifuged at 10,000 g for 10 min. DNA extraction from bacterial colonies was performed by suspending the colonies of interest in 200 µl of sterile PBS and processing as described above. A 2 µl aliquot of the supernatant was used as a DNA template for each PCR.

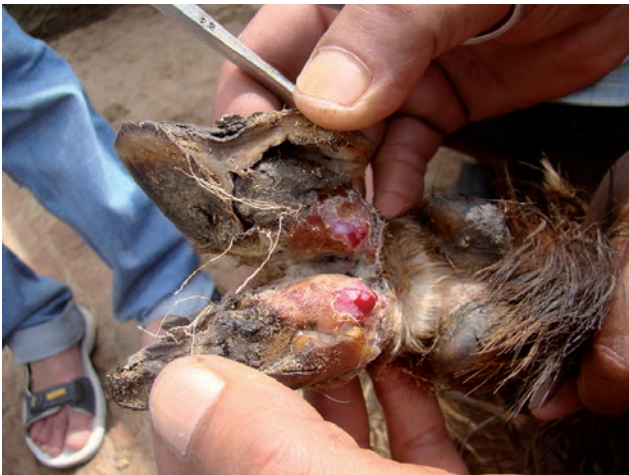Amplification of desired gene products

All PCR amplifications were performed in a 25 µl volume in 0.2 ml thin-walled PCR tubes (Tarson, India). In all cases the PCR mixture contained a final concentration of 2 mM MgCl₂, 0.2 mM of each 2'-deoxynucleoside 5'-triphosphate (dNTP), 2.5 µl of 10×PCR buffer and 1U of *Taq*DNA Polymerase (Promega corporation, Madison, USA).

a) Interdigital dermatitis in a goat



b) Separation of the hoof wall and sloughed off surface of the foot pad



c) Greenish pus oozing out of the interdigital space

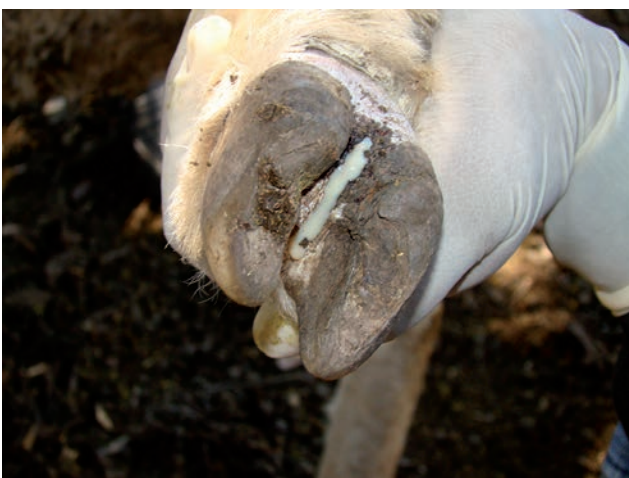

Fig. 2
Severity of various foot lesions in goats

Oligonucleotide primers used in the present study were procured from M/S Integrated DNA Technologies, Inc., USA. Deionised water was used as a control. Amplification was carried out in a GeneAmp PCR System 9700 Thermal Cycler (Applied Biosystems, USA).

Detection of 16S rDNA gene of *Dichelobacter nodosus* by polymerase chain reaction

Oligonucleotide primers specific for the detection of 16S rDNA gene (FP-5'-CGGGGTTATGTAGCTTGC-3' and RP-5'-TCGGTACCGAGTATTTCTACCCAACACCT-3') were used (25). PCR amplification was performed under the following conditions: incubation at 94°C for 2 min, five cycles of PCR at 94°C for 30 s, 60°C for 30 s and 72°C for 30 s, 25 cycles of PCR at 94°C for 30 s, 58°C for 30 s and 72°C for 30 s, and final extension at 72°C for 4 min.

A two-step PCR (26) was also performed on the samples that did not yield positive results by conventional PCR.

Isolation of *Dichelobacter nodosus* from clinical samples

For isolation of *D. nodosus*, one of the samples taken in duplicate was streaked on tripticase-arginine-serine (TAS) agar medium with 4% hoof powder (27) at the site of collection. After inoculation, the plates were placed immediately in a 2.5-litre anaerobic jar (Oxoid, UK) with Anaerogas Pack (HiMedia, Mumbai, India) and transported to the laboratory for incubation at 37°C. After five days of incubation, suspected colonies (27) were subcultured on the same medium until they were free from contaminating bacteria. They were then subcultured on TAS agar medium containing 2% hoof powder until pure colonies of *D. nodosus* were obtained. Plates that did not show any characteristic growth after an initial five days of incubation were incubated for another seven days before being discarded as negative.

Confirmation of the isolates as *D. nodosus* was done by demonstration of the typical cellular morphology in Gram-stained smears and detection of species-specific 16S rRNA gene by PCR using species-specific primers as described above.

Serogrouping of *Dichelobacter nodosus* positive samples by multiplex polymerase chain reaction

PCR-positive samples and *D. nodosus* isolates were subjected to serogrouping with multiplex PCR (m-PCR) using nine (A–I) serogroup specific primers (28). Multiplex PCR was performed on each DNA sample using a set of three primers. The amplification conditions for m-PCR were similar to those of the single PCR described above for

the detection of 16S rRNA gene of *D. nodosus* except for an increased concentration of the forward primers (2.5 times) as compared to the reverse primers.

Virulence determination of *Dichelobacter nodosus*

Detection of Integrase A (*intA*) gene by polymerase chain reaction

To ascertain the virulent or benign status, samples positive for *D. nodosus* were screened for the presence of the *intA* gene. Detection of *intA* was carried out using a PCR-based method previously described by Cheetham *et al.* (29). This PCR-based assay was also used to test DNA extracted from the cultures grown on plates.

Gelatine gel protease thermostability assay

Isolates were subjected to a gelatine gel protease thermostability assay for virulence determination. The gelatine gel protease test was carried out as per the procedure described by Palmer (30).

Detection of *Fusobacterium necrophorum* by polymerase chain reaction

DNA extracted from the field samples was tested for the presence of leukotoxin gene (*lktA*) specific to *F. necrophorum* using primer pair (*lktA*-F-5' ACAATCGGAGTAGTAGGTTTC 3' and *lktA*-R- 5' ATTTGGTAACTGCCACTGC 3') and thermal cycle conditions as per earlier published protocols by Bennett *et al.* (31).

Detection of *Trueperella pyogenes* by polymerase chain reaction

DNA extracted from the field samples by boiling method was used as a template and tested for the presence of the *pyolysin* (*plo*) gene of *T. pyogenes* using primer pair (F-5'-GGCCCGAATGTCACCGC-3' and R-5'-AACTCCGCCTCTAGCGC-3') and thermal cycle conditions as per the earlier published work by Billington *et al.* (32).

Isolation and identification of aerobic bacteria

All of the 216 swabs (duplicate) that were transported on ice were streaked on blood agar containing 4% defibrinated sheep blood and the plates were incubated aerobically at 37°C for 24–48 h. The resulting colonies were subcultured on the same media until purified. Identification of various bacterial genera was done by examination of colony morphology, type of haemolysis, Gram-staining of bacterial smears, and biochemical tests, including catalase, oxidase, coagulase, nitrate reduction and sugar fermentation tests as per standard protocols (33).

Results

Prevalence of *Dichelobacter nodosus* in Himachal Pradesh and bordering districts of Jammu and Kashmir

Among a total surveyed population of 27,586 animals comprised of 15,006 sheep and 12,580 goats, 2,753 animals were examined and 216 (7.84%) samples were collected from sheep and goats suffering from foot lesions. Only 14 samples were positive for *D. nodosus*, either by direct PCR or upon culturing, thus giving an overall positive percentage of 6.48%.

The prevalence of footrot was calculated by extrapolating the prevalence from the examined animals. Overall prevalence of footrot was 0.5% (14/2,753). The highest prevalence of 14% (7/50) was recorded in the Kishtwar district (J&K) followed by 0.56% (6/1,053) in the Kangra district (HP) and 0.5% (1/200) in the Chamba district (HP).

Most cases of lameness were encountered in the months of August to October. A total of 216 diagnostic samples were collected: 137 during the months of August to October; 45 during December to April and 34 during May to July.

Detection of *Dichelobacter nodosus* by direct polymerase chain reaction and isolation from samples collected from foot lesions

Out of the 216 samples collected, 13 (6.01%) samples were positive by direct PCR determined by the amplification of the 783 bp gene product characteristic of the 16S rDNA gene of *D. nodosus*. However, one of the samples that was negative on direct PCR revealed the presence of *D. nodosus* colonies on TAS media, which was later confirmed by performing the PCR on DNA extracted from these colonies, raising the number of positive samples to 14 (6.48%).

In total, 7/173 (4.04%) samples collected from HP were positive for *D. nodosus*. All the positive samples were from goats.

The geographical distribution of *D. nodosus* in HP revealed that out of 29 foot swabs collected from the Chamba district, only one sample from a Gaddi goat (named after the Gaddi community which lives in the region) was positive for *D. nodosus* (3.44%). A total of 6/55 (10.90%) samples collected from the Kangra district were positive for *D. nodosus*, all of which also came from goats. Out of these six samples, five were from Chegu goats kept at a local livestock farm in the Kangra district. These included the sample that was negative on direct PCR as mentioned previously and one from a Gaddi goat that was sampled from the Kandbari village in the Kangra district.

In the district of Kishtwar (J&K), 7/43 (16.27%) samples were positive for *D. nodosus*, all of them from a local breed of goat. All the samples that tested positive for *D. nodosus* were collected from the Marwah village in the Wadwan district (J&K).

The two-step PCR did not yield any further positive samples. Only the positive control could be amplified with this method and all the negative samples by conventional PCR were also negative by the two-step PCR.

Three *D. nodosus* isolates were recovered from the 216 samples processed on TAS media. However, only two of the swabs that yielded the isolates of *D. nodosus* were also positive by direct PCR, whereas the third sample was negative on direct PCR.

Serological diversity of *Dichelobacter nodosus*

All the *D. nodosus* isolates revealed an amplicon of 283 bp characteristic of serogroup B. The samples yielding positive results by conventional PCR were also serogrouped using m-PCR. All of the 13 samples yielded an amplicon of 283 bp, which specifies serogroup B. None of the samples that were positive either by PCR or on isolation belonged to any other serogroups.

Virulence status of *Dichelobacter nodosus*

Distribution of virulent *intA* gene among *Dichelobacter nodosus* positive samples

The three isolates of *D. nodosus* obtained from culture were screened to ascertain their virulence status and found to be 'virulent type' depicting a PCR product of 530 bp specific to *intA* of *D. nodosus*.

All 13 DNA samples yielding positive amplicons on direct PCR for *D. nodosus* were also screened for the presence of *intA*. Out of these 13 samples only seven (including two samples that also revealed *D. nodosus* colonies) revealed an amplicon of 530 bp. Therefore, a total of 8 (57.14%) out of 14 positive samples harboured virulent type *D. nodosus* of which five were from the district of Kangra and three were from the district of Kishtwar (J&K).

Gelatine gel protease thermostability assay of isolates

All of the three isolates of *D. nodosus* were subjected to a gelatine gel protease thermostability assay. Irrespective of their origin, all produced thermostable protease.

Detection of *Fusobacterium necrophorum*

A total of 45/216 (20.83%) samples were positive for *F. necrophorum* by PCR. These samples yielded amplicons of 402 bp for *lktA* specific to *F. necrophorum* (31).

In HP, 40/173 (23.12%) samples tested positive for *F. necrophorum*. Of these positive samples, 35 (20.23%) were from goats and five (2.89%) were from sheep. In the Kishtwar district of J&K, 5/43 (11.62%) tested positive for *F. necrophorum*, three of which were from goats (6.97%) and two (4.65%) from sheep.

Detection of *Trueperella pyogenes*

A total of 44/216 (20.37%) samples collected from HP and the bordering district of Kishtwar in J&K were positive for *T. pyogenes* and yielded an amplicon of 270 bp.

In HP, 37/173 (21.38%) samples tested positive for the presence of *T. pyogenes*. Of these 37 positive samples, 32 (18.49%) were from goats and five (2.87%) from sheep. In the Kishtwar district, 7/43 (16.27%) of the foot swabs collected tested positive for *T. pyogenes*, which included two (4.65%) samples from goats and five (11.62%) from sheep.

Taking into consideration mixed infections (Table I), a total of seven samples tested positive for both *T. pyogenes* and *F. necrophorum*: two samples were from goats of the Gaddi breed reared at a local livestock farm in Palampur, Kangra district; two samples were from a local non-descriptive breed of goat in Marwahm, Kishtwar district; and three samples were from the Gaddi breed of goat in Manali, Kullu district. Interestingly, three samples out of 216 samples were positive for all three bacteria (*D. nodosus*, *T. pyogenes*, *F. necrophorum*). All the samples were from a local livestock farm.

Detection of aerobic bacteria

Among 216 swabs inoculated on sheep blood agar, 205 swabs yielded bacterial colonies predominantly belonging to *Staphylococcus* spp. and *Bacillus* spp. followed by *Corynebacterium* spp. and *Micrococcus* spp. The bacterial isolates were present individually or in combination.

Table I
Distribution of samples by organism

Results of detection for different organisms	No. of samples (Total samples = 216)
<i>Dichelobacter nodosus</i> only	10
<i>Fusobacterium necrophorum</i> only	34
<i>Trueperella pyogenes</i> only	34
<i>D. nodosus</i> and <i>F. necrophorum</i>	1
<i>F. necrophorum</i> and <i>T. pyogenes</i>	7
<i>D. nodosus</i> , <i>F. necrophorum</i> and <i>T. pyogenes</i>	3
Negative for <i>D. nodosus</i> , <i>F. necrophorum</i> and <i>T. pyogenes</i>	127

Discussion

Infectious lameness of sheep and goats causes extensive morbidity worldwide, including in India. The present study focused primarily on HP and the bordering areas of J&K where footrot is of major concern (17, 18, 19, 20, 21). The state of HP has geoclimatic conditions and husbandry practices similar to J&K and rearing of sheep and goats is a major activity for the Gaddi community and marginal farmers. Although flocks of sheep and goats suffering from footrot-like disease had been reported in the past in HP (Verma *et al.*, unpublished data), the disease was never confirmed. The present study is the first of its kind that determines the prevalence of infectious lameness with a specific focus on footrot. During the period of March 2010 to May 2011, several flocks of sheep and goats were visited in seven districts of HP and the Kishtwar district of J&K. The Kishtwar district adjoins Chamba and has never been the focus of this kind of study.

The highest number of cases of lameness were reported in the months from August to October (137/216) after a brief period of rainfall. At this time of year, the animals start migrating back towards the plains, passing through the areas where hard rough rocks predispose them to foot injuries and the sub-temperate and rainy climate of the region plays an additional role in establishing foot lesions. Similar observations have been made from the south Indian states of Andhra Pradesh and Tamil Nadu, where an increased incidence of footrot was reported during monsoon, with a complete lack of footrot during the dry periods (22). In the flocks under investigation, limping and associated symptoms of lameness were noted by the owners during the months of monsoon when the animals were on the upper elevations of the areas. Mountainous terrain with no means of transportation and a walking distance of six to eight hours make it hard to sample and provide veterinary help to suffering sheep and goats. Similar terrain and logistical difficulties were encountered when flocks of sheep and goats were sampled in the present study, especially in the districts of Chamba, Kangra and Kullu. As per the owners' description, on average, each sheep and goat flock had around 10–20% of its animals exhibiting signs of lameness during, or in the months following, monsoon rains. The overall prevalence of lameness from March 2010 to May 2011 was 7.8%. *Dichelobacter nodosus* was detected or recovered from 6.48% of the lame animals. However, the prevalence was much higher for *F. necrophorum* and *T. pyogenes*. The overall prevalence of *D. nodosus* in flocks surveyed was 0.5%, whereas the total prevalence in HP was only 0.25%. It is a well-known fact that recovery or isolation of *D. nodosus*, which is a strict anaerobe, is difficult and the stage of footrot also determines the load of this microorganism in the foot lesions (12). There could be other reasons (i.e. poor nutrition, viral infections, physical

injuries) for this phenotype, apart from an infectious aetiology, and this requires investigation.

Surprisingly, all the animals that were positive for *D. nodosus* were goats (five belonging to the Chegu breed, two belonging to the Gaddi breed and seven indigenous goats from Kishtwar). Earlier studies carried out in the state of J&K (18) had shown that close to 28% of goats suffering from foot lesions were positive for footrot. However, subsequent studies reported the occurrence of footrot mostly in sheep in this region. It is not clear whether it was only sheep that suffered in these studies (19, 20, 21) or whether goats were not sampled as part of the study design. Since this is the first systematic study of this kind on footrot in this region, it is not known currently whether the disease is limited only to goats or whether the Gaddi sheep are resistant or whether the sheep do not become infected because, unlike goats, they do not engage in exploratory and active browsing behaviours. Goats tend to climb trees and thorny bushes to browse and, thus, there is a higher risk of acquiring foot and leg injuries predisposing them to infections. Genetic factors or species variation also cannot be ruled out (23). The isolation of *D. nodosus* from Chegu goats that were being reared at a local livestock farm may have been the result of a change in environment. To test their adaptability and to see if they were suited to sub-temperate conditions, these goats, which were grazing in the High Hills in the temperate region of Lahaul and Spiti, were brought down to the sub-temperate Mid-Hills areas. The area of Lahaul and Spiti receives less rainfall and the temperature drops to as low as -20°C in the winter. Most of the area is dry and rocky. Shifting the animals from their natural habitat to sub-temperate humid areas in the Mid Hills may be a factor that predisposed them to infection with *D. nodosus*.

The sheep and goat rearing communities of the districts of Chamba and Kangra follow a route leading to the highland pastures in the Kashmir region, J&K, where footrot has been reported to be a major concern (this study also revealed the highest prevalence of footrot in the district of Kishtwar, J&K). The introduction of the bacterium *D. nodosus* into HP could possibly have been from J&K when the owners, along with their flocks, returned from the pastures and moved back to their respective villages.

Only three isolates of *D. nodosus* were recovered from 216 microbiologically processed samples. These positive samples originated from Chegu goats housed at a local livestock farm in Palampur. In total, there were 14 samples positive for *D. nodosus*, however, only three isolates could be cultured on TAS media, resulting in a poor isolation recovery of 21.42%. This shows once again that this bacterium is hard to grow and, more importantly, it is very difficult to purify it from a plethora of other facultatively growing anaerobes. Furthermore, strict precautions need

to be taken while sampling, and inoculation onto an appropriate medium should be done at the sampling site or the appropriate conditions need to be maintained while transporting the infected material back to the laboratory for isolation. The samples positive for *D. nodosus*, either by isolation or by direct PCR, belonged to serogroup B, establishing that serogroup B is the predominant serogroup associated with footrot in HP and the bordering district of Kishtwar. Serogroup B has also been reported to be the most prevalent serogroup in the bordering state of J&K (18, 19, 20, 21). Serogroup B has also been reported to be the predominant serogroup in Bhutan (34), Australia (35), Great Britain (36) and New Zealand (37).

Failure of detection by PCR from one of the samples from which an isolate of *D. nodosus* was obtained may be attributed to the presence of inhibitory substances in the crude DNA template. Similar findings have been reported previously (19, 28). None of the samples taken from asymptomatic animals gave positive results for *D. nodosus* by direct PCR or by isolation.

As far as the virulence of the *D. nodosus* isolates is concerned, all three isolates were positive for phenotype-based protease enzyme activity. Virulence detection by *intA* PCR on 14 DNA samples (including DNA from three isolates) showed that more than half of the samples were harbouring virulent *D. nodosus*. These tests have been used previously to establish the virulent nature of an isolate, however, their relevance as true virulence markers has been questioned (38) since the clinical disease diagnosis does not always corroborate with the presence of virulence markers. The reason the tests have been previously questioned (38) is that only 40.8% of isolates were positive on both the gelatine gel assay and the *intA* gene amplification, whereas 92.9% were virulent on either the gelatine gel assay or *intA* gene analysis. This emphasises the need for the development of new tests that will clearly elucidate the nature of the isolate and are accurate, economical and less time consuming. In this direction, more recently, Stauble *et al.* (39) have developed a competitive real-time PCR based on allelic discrimination of the protease genes *AprV2* and *AprB2*. The latter encodes for arginine instead of tyrosine at position 92 in the mature *AprV2* protease, which allows direct detection and differentiation of virulent and benign *D. nodosus* from interdigital skin swabs in a single test. The recent findings (40), based on analysis of the genomes of 103 isolates of *D. nodosus* from different regions of the world, has revealed a bimodal population structure that is globally conserved. This data provided evidence that virulent and benign isolates represent two distinct forms of *D. nodosus* strains correlating perfectly with the single amino acid difference between the *AprV2* and *AprB2* protease. This type of comprehensive data has a great bearing on future diagnostics and vaccine development.

Of the 216 samples tested for *F. necrophorum*, 45 (20.83%) were positive by direct PCR. *Fusobacterium necrophorum* has been shown to cause lameness in sheep in experimental pens (41, 42). By virtue of being ubiquitous in nature (43) and an inhabitant of the normal alimentary tract of animals (44), even a minor injury to the hoof or denaturation of the skin in waterlogged barns and pastures can lead to entry of the bacteria and the establishment of infection. Involvement of *F. necrophorum* in conjunction with *D. nodosus* has also been suggested in field conditions, with 17/42 samples positive for both *F. necrophorum* and *D. nodosus* (31); whereas only two were positive for *F. necrophorum* alone and two for *D. nodosus* alone. However, these authors (31) did not test for the presence of other bacteria that have been implicated in causing foot abscess in conjunction with *F. necrophorum*, e.g. *T. pyogenes*.

A total of 44 (20.37%) samples were positive for *T. pyogenes* out of 216 samples. *Trueperella pyogenes* has been reported to be among the microorganisms present in the mucous membranes of the urogenital tract, the upper respiratory tract and the ruminal wall of domestic animals (31). Weight gain by sheep and goats due to ample availability of good quality fodder on highland pastures, along with foot injuries and sloughing off of skin in consistently moist conditions during the monsoon period, predispose animals to entry and infection by both *F. necrophorum* (45) and *T. pyogenes* (46).

Clinical examination of the affected hooves in limping sheep and goats revealed characteristic swelling of the soft tissue (mainly towards the hooves) along with necrotising or purulent infection. In some of the advanced cases, greenish-creamy pus was oozing out of these abscesses, usually from the coronary band. These animals were examined in highland pastures for a suspected outbreak of footrot but their foot lesions were more characteristic of a foot abscess. Other authors have also made similar observations (45).

The isolation of facultative anaerobes from foot lesions points towards their possible role in creating conditions conducive to the establishment of *D. nodosus* and subsequent development of pathology. Similar observations have been reported previously (47), where the presence of sequences similar to those of bacteria such as *Staphylococcus* spp., *Micrococcus* spp., *Corynebacterium* spp. and *Peptostreptococcus* spp. was noted. Eleven of the samples collected in this study did not yield any growth when processed aerobically. This could have happened due to several reasons, including faulty sampling or drying up of the swabs during transportation.

The detection of *F. necrophorum* and *T. pyogenes* in high numbers from cases of hoof infection indicates an important role for these organisms in inducing morbidity in migratory

sheep and goats. The study concludes that these bacteria are an important cause of infectious lameness in the HP region of India. Given the fact that *D. nodosus* has now been confirmed in HP and the lack of rational preventive plans in place, there is a high probability of it establishing a habitat and an infection niche in this area, potentially resulting in endemic infection. Infectious lameness due to footrot has been reported to be treated with a single dose of long-acting antibiotics; however, the cases of lameness due to foot abscesses require prolonged use of antibiotics and even after administration of antibiotics, the prognosis for advanced cases remains bleak (14). The animals suffering from infectious lameness are unable to keep pace with the rest of the flock during migration. Other healthy animals are put at risk of infection and, therefore, owners are forced to sell their animals at low prices. This inflicts losses both in time and money (draining the owners of their savings). This study has shown that lameness is a serious problem in migratory small ruminants and requires short-term therapeutic management and preventive strategies against *D. nodosus*, *E. necrophorum* and *T. pyogenes*. A medium-term strategy could be to develop a combined vaccine composed of non-competitive antigens from these organisms to reduce pain and suffering in the animals and also curtail losses to sheep- and goat-rearing communities. Breeding of animals for resistance to footrot and other infections could be considered as a long-term goal.

Conclusion

This study detected the presence of *D. nodosus* in foot lesions of small ruminants from the state of HP for the first time. However, the prevalence was low and further investigation is warranted. Footrot caused by *D. nodosus* may have occurred due to mixing of migratory flocks at pastures spanning the borders of the two states of HP and J&K. ■

Given that *E. necrophorum* and *T. pyogenes* are associated with the majority of the cases of lameness in the state of HP, strict surveillance and adoption of appropriate preventive strategies is necessary. For the future, a combined vaccine targeting *D. nodosus*, *E. necrophorum* and *T. pyogenes* could prove beneficial. It may protect the sheep and goat population in the Himalayan region, particularly in J&K and HP, and also bring economic gains to the sheep- and goat-rearing communities.

Acknowledgements

This work was possible due to the financial assistance received under the National Agricultural Innovation Project of the Indian Council of Agricultural Research, New Delhi.

The authors thank the officers of the Animal Husbandry Departments in HP & J&K for logistic support.

Boiteries d'origine infectieuse (dues notamment à des germes anaérobies) affectant les troupeaux migrants d'ovins et de caprins dans le nord-ouest de l'Inde

A.H. Wani, S. Verma, M. Sharma & S.A. Wani

Résumé

Plusieurs espèces bactériennes, dont *Dichelobacter nodosus*, *Fusobacterium necrophorum*, *Trueperella pyogenes* (précédemment *Arcanobacterium pyogenes*) et *Treponema* spp., ont été associées à des infections affectant les populations d'ovins et de caprins et se manifestant par des boiteries. Les auteurs présentent les résultats d'une étude cherchant à établir les causes des boiteries d'origine infectieuse observées dans le nord-ouest de l'Himalaya, en particulier dans l'Himachal Pradesh, État de l'Inde qui n'avait jamais fait l'objet d'une telle étude précédemment. Au total, 27 586 animaux ont été examinés (15 006 moutons et 12 580 chèvres) et des échantillons ont été prélevés sur les lésions podales de 216 d'entre eux. La présence de *D. nodosus* a été détectée dans 6,48 % des échantillons (soit 14/216), tandis que *F. necrophorum* était présent dans 20,83 % des échantillons (soit 45/216) et *T. pyogenes* dans 20,37 % des échantillons (soit 44/216). La présence simultanée des trois bactéries précitées dans un même échantillon de lésions podales a été observée à trois occasions. Les échantillons positifs provenaient pour la plupart de l'État de l'Himachal Pradesh, appartenant à l'État de Jammu et Kashmir où le piétin est endémique. La confirmation de la présence du piétin dans l'Himachal Pradesh et le grand nombre de détections de *F. necrophorum* et de *T. pyogenes* dans les lésions du pied ou des ongles soulignent l'importance du rôle joué par ces micro-organismes dans les pathologies affectant les troupeaux migrants d'ovins et des caprins. La présente étude rapporte la première détection confirmée de *D. nodosus* à partir de cas de piétin survenus dans l'Himachal Pradesh. Au vu des rapports récents sur le rôle joué par *F. necrophorum* en tant qu'agent pathogène secondaire potentiellement responsable d'une aggravation de l'infection causée par le piétin, il a été proposé de mettre au point un vaccin combiné afin de prévenir les boiteries chez les ovins et les caprins du nord-ouest de l'Himalaya.

Mots-clés

Abcès des pieds – Boiteries d'origine infectieuse – Caprin – *Dichelobacter nodosus* – *Fusobacterium necrophorum* – Germes anaérobies – Ovin – Piétin – *Trueperella pyogenes*.



Cojera infecciosa en ovejas y cabras migratorias en la India noroccidental, en especial la causada por microorganismos anaerobios

A.H. Wani, S. Verma, M. Sharma & S.A. Wani

Resumen

Varias especies bacterianas, en particular *Dichelobacter nodosus*, *Fusobacterium necrophorum*, *Trueperella pyogenes* (anteriormente *Arcanobacterium pyogenes*) y *Treponema* spp., han sido relacionadas con patologías infecciosas que afectan a poblaciones ovinas y caprinas y provocan cojera, entre otras manifestaciones. Los autores describen un estudio sobre las causas de la cojera de origen infeccioso en la región noroccidental del Himalaya, en especial Himachal Pradesh, donde hasta la fecha no se había realizado ningún estudio. De la población analizada, formada por un total de 27.586 animales (15.006 ovejas y 12.580 cabras), se obtuvieron 216 muestras de lesiones podales. Un 6,48% (14/216) de las muestras resultaron positivas para *D. nodosus*, un 20,83% (45/216) para *F. necrophorum* y un 20,37% (44/216) para *T. pyogenes*. En tres casos, las tres bacterias mencionadas estaban presentes en la misma lesión. Las muestras positivas procedían mayoritariamente de zonas del estado de Himachal Pradesh contiguas al estado de Jammu y Cachemira, donde la dermatitis interdigital es endémica. La confirmación de la presencia de dermatitis interdigital en Himachal Pradesh y el hecho de que se detectaran *F. necrophorum* y *T. pyogenes* en un gran número de casos de infección de la pezuña ponen de relieve la importante influencia de estos microorganismos en la morbilidad de las ovejas y cabras migratorias. La investigación aquí descrita confirmó asimismo, por primera vez en Himachal Pradesh, la presencia de *D. nodosus* ligada a casos de dermatitis interdigital. Teniendo en cuenta los nuevos datos que revelan la intervención de *F. necrophorum* como patógeno secundario y su posible función en el agravamiento de la infección resultante de la dermatitis interdigital, los autores proponen que se elabore una vacuna combinada para prevenir la cojera en la población ovina y caprina de la región noroccidental del Himalaya.

Palabras clave

Absceso podal – Caprino – Cojera infecciosa – Dermatitis interdigital – *Dichelobacter nodosus* – *Fusobacterium necrophorum* – Microorganismos anaerobios – Ovino – *Trueperella pyogenes*.

References

- Goddard P, Waterhouse T, Dwyer C. & Stott A. (2006). – The perception of welfare of sheep in extensive systems. *Small Rum. Res.*, **62** (3), 215–222. doi:10.1016/j.smallrumres.2005.08.016.
- Nieuwhof G.J. & Bishop S.C. (2005). – Costs of the major endemic diseases of sheep in Great Britain and the potential benefits of reduction in disease impacts. *Anim. Sci.*, **81** (1), 57–67. doi:10.1079/ASC41010023.
- Green L.E. & George T.R.N. (2008). – Assessment of current knowledge of footrot in sheep with particular reference to *Dichelobacter nodosus* and implications for elimination or control strategies for sheep in Great Britain. *Vet. J.*, **175** (2), 173–180. doi:10.1016/j.tvjl.2007.01.014.
- Marshall D.J., Walker R.J., Cullis B.R. & Luff M.F. (1991). – The effect of footrot on body weight and wool growth of sheep. *Aust. Vet. J.*, **68** (2), 45–49. doi:10.1111/j.1751-0813.1991.tb03126.x.

5. Egerton J.R. (2000). – Foot rot and other foot conditions. In *Diseases of sheep* (W.B. Martin & I.D. Aitken, eds). Blackwell Science Ltd, Edinburgh, 243–249.
6. Lavin S., Ruiz-Bascarán M., Marco I., Abarca M.L., Crespo M.J. & Franch J. (2004). – Foot infections associated with *Arcanobacterium pyogenes* in free-living fallow deer (*Dama dama*). *J. Wildl. Dis.*, **40** (3), 607–611. doi:10.7589/0090-3558-40.3.607.
7. Dhawi A., Hart C.A., Demirkan I., Davies I.H. & Carter S.D. (2005). – Bovine digital dermatitis and severe virulent ovine footrot: a common spirochetal pathogenesis. *Vet. J.*, **169** (2), 232–241. doi:10.1016/j.tvjl.2004.01.029.
8. Quinn P.J., Markey B.K., Carter M.E., Donnelly W.J.C. & Leonard F.C. (2002). – Veterinary microbiology and microbial disease. Blackwell Science, 406 pp.
9. Wassink G.J., Grogono-Thomas R., Moore L.J. & Green L.E. (2003). – Risk factors associated with the prevalence of footrot in sheep from 1999 to 2000. *Vet. Rec.*, **152** (12), 351–358. doi:10.1136/vr.152.12.351.
10. Kaler J. & Green L.E. (2008). – Naming and recognition of six foot lesions of sheep using written and pictorial information: a study of 809 English sheep farmers. *Prev. Vet. Med.*, **83** (1), 52–64. doi:10.1016/j.prevetmed.2007.06.003.
11. Graham N.P.H. & Egerton J.R. (1968). – Pathogenesis of ovine footrot: the role of some environmental factors. *Aust. Vet. J.*, **44** (5), 235–240. doi:10.1111/j.1751-0813.1968.tb09092.x.
12. Witcomb L.A., Green L.E., Kaler J., Ul-Hassan A., Calvo-Bado L.A., Medley G.F., Grogono-Thomas R. & Wellington E.M.H. (2014). – A longitudinal study of the role of *Dichelobacter nodosus* and *Fusobacterium necrophorum* load in initiation and severity of footrot in sheep. *Prev. Vet. Med.*, **115** (1–2), 48–55. doi:10.1016/j.prevetmed.2014.03.004.
13. Witcomb L.A., Green L.E., Kaler J., Calvo-Bado L.A., Russell C.L., Smith E.M., Grogono-Thomas R. & Wellington E.M.H. (2015). – First study of pathogen load and localisation of ovine footrot using fluorescence in situ hybridisation (FISH). *Vet. Microbiol.*, **176** (3–4), 321–327. doi:10.1016/j.vetmic.2015.01.022.
14. Kahn C.M. & Line S. (2010). – Lameness in sheep. In *The Merck veterinary manual*, 10th Ed. (C.M. Kahn & S. Line, eds). Merck, Rahway, New Jersey, 1065 pp.
15. National Dairy Development Board (2012). – Livestock population in India by species. National Dairy Development Board, Gujarat, India. Available at www.nddb.org/information/stats/pop (accessed on 1 December 2015).
16. Department of Animal Husbandry (Government of Himachal Pradesh) (2007). – Districtwise number of various livestock species and poultry etc. in Himachal Pradesh (provisional figures drawn from householdwise data entry of 18th livestock census – 2007). Department of Animal Husbandry, Shimla, India. Available at www.hpagrisnet.gov.in/hpagris/AnimalHusbandry/Default.aspx?SiteID=3&PageID=1063 (accessed on 1 December 2015).
17. Wani S.A., Samanta I., Buchh A.S. & Bhat M.A. (2004). – Molecular detection and characterization of *Dichelobacter nodosus* in ovine footrot in India. *Molec. Cell. Probes*, **18** (5), 289–291. doi:10.1016/j.mcp.2004.03.004.
18. Wani S.A., Samanta I. & Kawoosa S. (2007). – Isolation and characterization of *Dichelobacter nodosus* from ovine and caprine footrot in Kashmir, India. *Res. Vet. Sci.*, **83** (2), 141–144. doi:10.1016/j.rvsc.2006.11.006.
19. Hussain I., Wani S.A., Qureshi S.D. & Farooq S. (2009). – Serological diversity and virulence determination of *Dichelobacter nodosus* from footrot in India. *Molec. Cell. Probes*, **23** (2), 112–114. doi:10.1016/j.mcp.2009.01.003.
20. Farooq S., Wani S.A., Hussain I. & Bhat M.A. (2010). – Prevalence of ovine footrot in Kashmir, India and molecular characterization of *Dichelobacter nodosus*. *Indian J. Anim. Sci.*, **80**, 826–830.
21. Rather M.A., Wani S.A., Hussain I., Bhat M.A., Kabli Z.A. & Magray S.N. (2011). – Determination of prevalence and economic impact of ovine footrot in central Kashmir India with isolation and molecular characterization of *Dichelobacter nodosus*. *Anaerobe*, **17** (2), 73–77. doi:10.1016/j.anaerobe.2011.02.003.
22. Sreenivasulu D., Vijayalakshmi S., Raniprameela D., Karthik A., Wani S.A. & Hussain I. (2013). – Prevalence of ovine footrot in the tropical climate of southern India and isolation and characterisation of *Dichelobacter nodosus*. *Rev. Sci. Tech. Off. Int. Epiz.*, **32** (3), 869–877.
23. Thomas N., Joseph S., Alex R., Raghavan K.C., Radhika G., Anto L. & Mohan S.G. (2011). – Genetic variation in resistance to caprine footrot by *Dichelobacter nodosus* in goats of Kerala. *Biotechnol. Anim. Husb.*, **27** (2), 235–240. doi:10.2298/BAH1102235T.
24. Egerton J.R. & Roberts D.S. (1971). – Vaccination against ovine footrot. *J. Comp. Pathol.*, **81** (2), 179–185. doi:10.1016/0021-9975(71)90091-0.
25. La Fontaine S., Egerton J.R. & Rood J.I. (1993). – Detection of *Dichelobacter nodosus* using species specific oligonucleotides as PCR primers. *Vet. Microbiol.*, **35** (1–2), 101–117. doi:10.1016/0378-1135(93)90119-R.
26. Belloy L., Giacometti M., Boujon P. & Waldvogel A. (2007). – Detection of *Dichelobacter nodosus* in wild ungulates (*Capra ibex ibex* and *Ovis aries musimon*) and domestic sheep suffering from footrot using a two-step polymerase chain reaction. *J. Wildl. Dis.*, **43** (1), 82–88. doi:10.7589/0090-3558-43.1.82.
27. Thorley C.M. (1976). – A simplified method for the isolation of *Bacteroides nodosus* from ovine footrot and studies on its colony morphology and serology. *J. Appl. Bacteriol.*, **40** (3), 301–309. doi:10.1111/j.1365-2672.1976.tb04178.x.
28. Dhungyel O.P., Whittington R.J. & Egerton J.R. (2002). – Serogroup specific single and multiplex PCR with pre-enrichment culture and immuno-magnetic bead capture for identifying strains of *D. nodosus* in sheep with footrot prior to vaccination. *Molec. Cell. Probes*, **16** (4), 285–296. doi:10.1006/mcpr.2002.0427.

29. Cheetham B.F., Tanjung L.R., Sutherland M., Druitt J., Green G., McFarlane J., Bailey G.D., Seaman J.T. & Katz M.E. (2006). – Improved diagnosis of virulent footrot using *intA* gene. *Vet. Microbiol.*, **116** (1–3), 166–174. doi:10.1016/j.vetmic.2006.04.018.
30. Palmer M.A. (1993). – A gelatin test to detect activity and stability of proteases produced by *Dichelobacter (Bacteroides) nodosus*. *Vet. Microbiol.*, **36** (1–2), 113–122. doi:10.1016/0378-1135(93)90133-R.
31. Bennett G., Hickford J., Sedcole R. & Zhou H. (2009). – *Dichelobacter nodosus*, *Fusobacterium necrophorum* and the epidemiology of footrot. *Anaerobe*, **15** (4), 173–176. doi:10.1016/j.anaerobe.2009.02.002.
32. Billington S.J., Post K.W. & Jost B.H. (2002). – Isolation of *Arcanobacterium (Actinomyces) pyogenes* from cases of feline otitis externa and canine cystitis. *J. Vet. Diagn. Invest.*, **14** (2), 159–162. doi:10.1177/104063870201400212.
33. Forbes B.A., Sahn D.E. & Weissfeld A.S. (2007) – Bailey and Scott's diagnostic microbiology, 12th Ed. Mosby, USA, 216–247.
34. Gurung R.B., Tshering P., Dhungyel O.P. & Egerton J.R. (2006). – Distribution and prevalence of footrot in Bhutan. *Vet. J.*, **171** (2), 346–351. doi:10.1016/j.tvjl.2004.11.012.
35. Claxton P.D., Ribeiro L.A. & Egerton J.R. (1983). – Classification of *Bacteroides nodosus* by agglutination tests. *Aust. Vet. J.*, **60** (11), 331–334. doi:10.1111/j.1751-0813.1983.tb02834.x.
36. Hindmarsh F. & Fraser J. (1985). – Serogrouping of *Bacteroides nodosus* isolated from ovine footrot in Britain. *Vet. Rec.*, **116** (7), 187–188. doi:10.1136/vr.116.7.187.
37. Kingsley D.F., Hindmarsh F.H., Liardet D.M. & Chetwin D.H. (1986). – Distribution of serogroups of *Bacteroides nodosus*, with particular reference to New Zealand and the United Kingdom. In *Footrot in ruminants* (D.J. Stewart, J.E. Peterson, N.M. Mckern & D.L. Emery, eds). Proc. of a workshop, Melbourne, 1985. CSIRO Press, Sydney, 143–146.
38. Dhungyel O.P., Hill A.E., Dhand N.K. & Whittington R.J. (2013). – Comparative study of the commonly used virulence tests for laboratory diagnosis of ovine footrot caused by *Dichelobacter nodosus* in Australia. *Vet. Microbiol.*, **162** (2–4), 756–760. doi:10.1016/j.vetmic.2012.09.028.
39. Stauble A., Steiner A., Frey J. & Kuhnerta P. (2014). – Simultaneous detection and discrimination of virulent and benign *Dichelobacter nodosus* in sheep of flocks affected by foot rot and in clinically healthy flocks by competitive real-time PCR. *J. Clin. Microbiol.*, **52** (4), 1228–1231. doi:10.1128/JCM.03485-13.
40. Kennan R.M., Gilhuus M., Frosth S., Seemann T., Dhungyel O.P., Whittington R.J., Boyce J.D., Powell D.R., Aspán A., Jorgensen H.J., Bulach D.M. & Rood J.I. (2014). – Genomic evidence for a globally distributed, bimodal population in the ovine footrot pathogen *Dichelobacter nodosus*. *mBio.*, **5** (5), e01821-14. doi:10.1128/mBio.01821-14.
41. Corner L.A., Collins N.D. & Vaughan J.A. (1996). – An experimental ovine foot abscess model using a *Fusobacterium necrophorum* biotype AB. *Vet. Microbiol.*, **48** (1–2), 1–7. doi:10.1016/0378-1135(95)00142-5.
42. Emery D.L., Vaughan J.A., Clark B.L. & Stewart D.J. (1986). – Virulence determinants of *Fusobacterium necrophorum* and their prophylactic potential in animals. In *Footrot in ruminants* (D.J. Stewart, J.E. Peterson, N.M. Mckern & D.L. Emery, eds). Proc. of a workshop, Melbourne, 1985. CSIRO Press, Sydney, 267–274.
43. Beveridge W.I.B. (1941). – Footrot in sheep: a transmissible disease due to infection with *Fusiformis nodosus*. *Bull. Counc. Sci. Ind. Res. Aust.*, **140**, 1–56.
44. Langworth B.F. (1977). – *Fusobacterium necrophorum*: its characteristics and role as an animal pathogen. *Bacteriol. Rev.*, **41** (2), 373–390.
45. Allan S. (2010). – Foot abscess in sheep. Primefact 987, 2nd Ed. Industry and Investment New South Wales, Sydney.
46. Gezon H.M., Bither H.D., Hanson L.A. & Thompson J.K. (1991). – Epizootic of external and internal abscesses in a large goat herd over a 16-year period. *J. Am. Vet. Med. Assoc.*, **198** (2), 257–263.
47. Calvo-Bado L.A., Oakley B.B., Dowd S.E., Green L.E., Medley G.F., Ul-Hassan A., Bateman V., Gaze W., Witcomb L., Thomas R.G., Kaler J., Russell C.L. & Wellington E.M.H. (2011). – Ovine pedomics: the first study of the ovine foot 16S rRNA-based microbiome. *ISME J.*, **5** (9), 1426–1437. doi:10.1038/ismej.2011.25.

