

Identification of *Dermatophilus congolensis* from lower leg dermatitis of cattle in Kerala, India

P.V. Tresamol ^{(1)*}, M.R. Saseendranath ⁽¹⁾, H. Subramanian ⁽²⁾, U.N. Pillai ⁽³⁾, M. Mini ⁽⁴⁾ & S. Ajithkumar ⁽³⁾

(1) Department of Veterinary Epidemiology and Preventive Medicine, College of Veterinary and Animal Sciences, Mannuthy, Thrissur, Kerala, PIN 680651, India

(2) Department of Veterinary Parasitology, College of Veterinary and Animal Sciences, Mannuthy, Thrissur, Kerala, PIN 680651, India

(3) Department of Clinical Veterinary Medicine, College of Veterinary and Animal Sciences, Mannuthy, Thrissur, Kerala, PIN 680651, India

(4) Department of Veterinary Microbiology, College of Veterinary and Animal Sciences, Mannuthy, Thrissur, Kerala, PIN 680651, India

*Corresponding author: pvtresamol@yahoo.co.in

Summary

This study was conducted to identify the aetiological agents associated with a particular type of lower leg dermatitis, locally called pododermatitis, among dairy cattle in Kerala. Skin scabs and scrapings were collected aseptically from 82 naturally occurring cases of lower leg dermatitis in cattle and were subjected to direct microscopical examination and bacterial and fungal culture. Microscopical examination of the skin scrapings with 10% potassium hydroxide revealed fungal spores in hair shafts from only two samples and did not reveal the presence of mites or other parasites. Fungal culture yielded dermatophytes from only five samples; these were identified as *Trichophyton mentagrophytes* in two cases, *T. verrucosum* in one case, *Epidermophyton floccosum* in one case and *Microsporum nanum* in one case. Microscopical examination of Giemsa- and Gram-stained smears of the scab material from the lesions from 72 cases revealed characteristic Gram-positive septate branching filaments with multiple rows of spherical to ovoid cocci, with a typical 'tram-track' appearance suggestive of *Dermatophilus congolensis*. Culture of the scab materials on sheep blood agar in the presence of 10% carbon dioxide yielded typical beta haemolytic colonies of *D. congolensis* from 75 samples. The isolates were further confirmed by the macroscopic and microscopic morphology of the colonies, and biochemical test results. This study confirmed the presence of dermatophilosis caused by *D. congolensis* in cattle in Kerala.

Keywords

Cattle – *Dermatophilus congolensis* – India – Kerala – Lower leg dermatitis – Pododermatitis.

Introduction

Dermatophilosis due to *Dermatophilus congolensis* is an exudative dermatitis which affects a wide range of animal species, including humans. The disease occurs in acute, subacute, chronic and latent forms, either in a generalised form or as localised lesions in different body sites, such as the dorsal region, the feet, the external genital area, mammary skin and the head area (1, 2). The disease is

characterised by proliferation of the epidermis to produce thickened crusts or scabs formed from palisaded layers of keratinocytes, serous exudation and infiltration of neutrophils (3). In Kerala, a particular type of dermatitis of the lower limbs of cattle, characterised by the formation of thick scabs and crusts with cracks and fissures, has occurred more frequently in recent years. This study was conducted to identify the aetiological agents associated with this type of lower leg dermatitis in cattle, which is known locally as pododermatitis.

Materials and methods

Skin scabs and scrapings were collected aseptically from 82 cases of naturally occurring lower leg dermatitis characterised by typical exudative dermatitis with matting of hairs and thick scab formation in cattle (Fig. 1) and were subjected to direct microscopical examination and culture. A portion of a skin scab was emulsified in a few drops of sterile distilled water on a clean glass slide, and smears were made and stained with Giemsa and Gram stains (4). Isolation of *D. congolensis* was carried out using Haalstra's technique with minor modifications (5). Skin scabs were minced with a sterile scalpel blade and placed in glass bottles. One millilitre of sterile water was added to each specimen. The bottles were allowed to stand open for three hours at room temperature. Each opened bottle was then transferred to a candle jar, and a candle was burned within the jar to obtain 10% carbon dioxide tension. After 15 minutes, the bottle was carefully removed; a loopful taken from the water surface was seeded on sheep blood agar plates and incubated at 37°C in 10% carbon dioxide for 24–48 h. The plates were then examined for colonies of *D. congolensis* (4). The isolates were stained by Gram's method and identification was carried out using various biochemical tests such as the catalase, oxidase, urease, nitrate, indole and DNase tests. The isolates were also checked for their ability to digest gelatine and Loeffler's coagulated serum and to hydrolyse starch and casein (6).

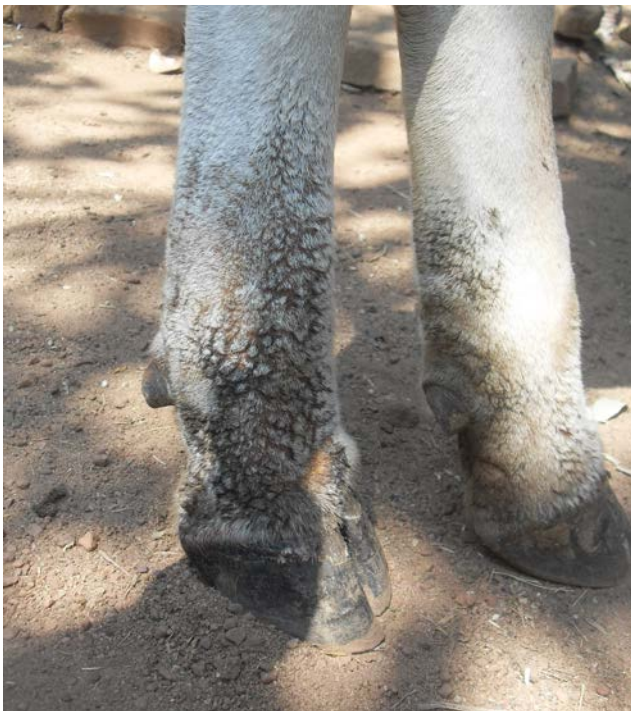

Fig.1
Dermatitis with matting of hairs and scab formation on limbs

The scabs and hairs were also inoculated into Sabouraud's dextrose agar supplemented with chloramphenicol and cycloheximide (SDA-CC) and dermatophyte test medium (DTM), and incubated at room temperature and at 37°C for primary isolation of dermatophytes. The isolates were identified from their colonial morphology and by microscopical examination using the wet mount and sticky tape method with lactophenol cotton blue stain. The hairs and scabs were also examined with 10% potassium hydroxide for the presence of fungal spores or mites.

Results

Microscopical examination of Giemsa- or Gram-stained smears of the scab material from the lesions revealed characteristic Gram-positive septate branching filaments which were longitudinally as well as transversely divided to form spherical or ovoid cocci in multiple rows, with the typical 'tram-track' appearance suggestive of *D. congolensis* (Figs 2 and 3). Out of 82 animals with characteristic lesions, scabs from 72 animals were positive for *D. congolensis*. The morphological characteristics of the organisms within hyphae were clearer with Giemsa stain than with Gram stain.

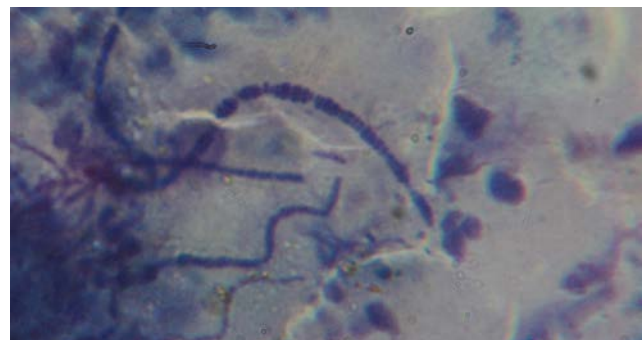


Fig.2
Tram-track appearance of *D. congolensis* in stained smears of scabs from lesions (Giemsa stain 1,000×)

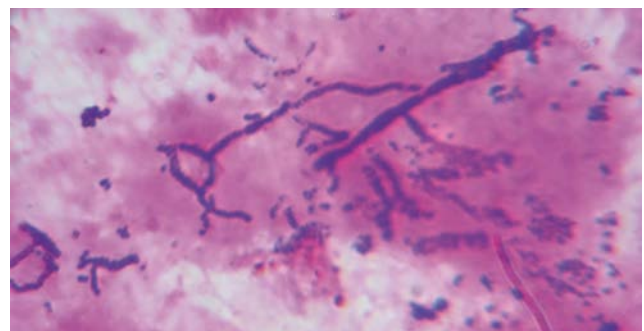


Fig.3
Branching filaments with septations in impression smears from lesions (Gram stain 1,000×)

Culture of the scab materials in sheep blood agar in the presence of 10% carbon dioxide in a candle jar yielded typical beta haemolytic colonies of *D. congolensis* in 75 samples (Fig. 4). Microscopical examination of organisms in Gram-stained smears from colonies revealed Gram-positive branching filaments in different stages of segmentation, and coccoid forms (Fig. 5).

Round or irregular greyish-white raised granular colonies, which were adherent and usually pitted the medium, were observed in positive samples after 24 h. There was great variation in the colonial morphology of different isolates and even of the same isolate on the same agar plate. There were variations in the shape, colour and texture of the colonies.

All the isolates were haemolytic, producing clear zones of beta haemolysis in 7% sheep blood agar within 24–72 h of incubation. The wet mount preparation of all the isolates revealed motile zoospores. The isolates were positive on the catalase and oxidase tests. All the isolates were urease positive, but showed negative results with the nitrate and indole tests. The isolates were able to digest gelatine and Loeffler's coagulated serum and showed hydrolysis of starch and casein. Eighteen isolates gave a positive reaction in the DNase test. All the isolates produced acid from glucose, fructose and sucrose within 24 h of incubation but showed variable results with maltose, mannitol and lactose. The isolates were unable to produce acid from sorbitol and xylose. None of the isolates produced gas from these sugars.

Inoculation of the scabs and hairs from the lesions into SDA-CC and DTM yielded dermatophytes in five samples during a period of two to three weeks at room temperature. These organisms were identified as *Trichophyton mentagrophytes* in two cases, *T. verrucosum* in one case, *Epidermophyton floccosum* in one case and *Microsporum*

nanum in one case. The remaining samples yielded no fungal growth during a period of four weeks. Direct microscopical examination of the skin scrapings with 10% potassium hydroxide revealed the presence of endothrix spores of dermatophytes within the hair shaft in two cases, which were also positive by fungal culture. No mites could be detected in the skin scrapings examined from the cases.

Discussion and conclusion

In this study, the aetiological agent of the particular form of lower leg dermatitis with matting of hair, thick scabs and cracks seen in cattle in Kerala was confirmed as *D. congolensis*. Although there are few reports on the prevalence of dermatophilosis among animals and humans in other states in India (7), this study confirmed dermatophilosis as the aetiology of the widespread lower leg dermatitis among cattle in Kerala.

Observation of the distinctive tram-track appearance of *D. congolensis* has been demonstrated as the most practical diagnostic method for dermatophilosis in several studies (2, 4, 8). The pleomorphic nature of *D. congolensis* in stained smears of scabs has been described, and the organism may be seen in any form of the various stages of its life cycle (2, 9). Scabs from ten animals with typical lesions were negative for *D. congolensis*. This may have been because the samples were collected during the healing stage or from chronic cases. Similar situations, where the stained smears taken from dried scabs collected from chronic cases showed low numbers of bacteria without the characteristic appearance of the organism, have been reported by Award and colleagues (1). The superiority of Giemsa stain over Gram stain for clear demonstration of *D. congolensis* was noted by Searcy and Hulland (10).

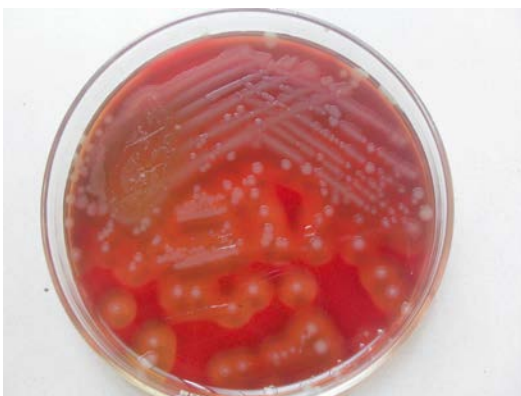

Fig. 4
Greyish-white haemolytic colonies of *D. congolensis* on sheep blood agar

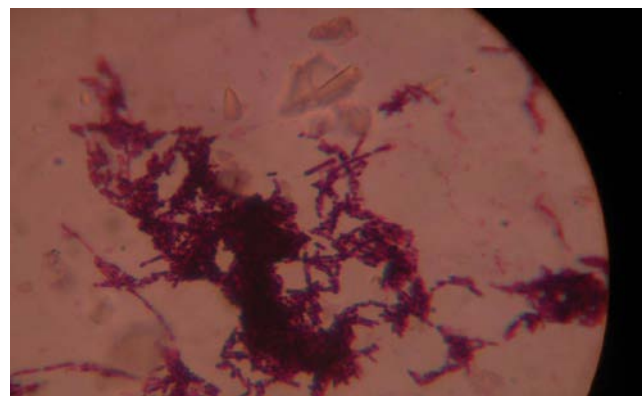


Fig. 5
Branching filaments of *D. congolensis* in different stages of segmentation from culture (Gram stain 1,000×)

Dermatophilus congolensis is a facultative anaerobe, and therefore isolation by the technique described by Haalstra (5) was found to be useful, and it also reduced contamination by other bacteria. The failure to isolate the organisms from seven cases may have been due to lack of viable organisms in the specimens, which occurs in the chronic or healing stages of disease, as described in several reports (1, 7, 11). Failure of isolation due to growth of commensal skin bacteria which inhibit the growth of *D. congolensis* has also been reported (12). There was great variation in the colonial morphology of different isolates and even of the same isolate on the same agar plate, as reported by Gordon and El-Nageh (13, 14). The biochemical characteristics of the isolates were in general agreement with previous findings (15, 16, 17). None of the isolates in this study produced gas from the sugars, but gas production from dextrose was reported by Nath *et al.* (17). The characteristic appearance of round or irregular greyish-white raised granular colonies which were adherent and usually pitted the medium was also observed by Pier and colleagues (18). The phenotypic characteristics of the isolates obtained were well correlated with the findings of Shaibu and co-workers (19).

Dermatophytes were isolated from five cases along with *D. congolensis*. Concurrent infection with *D. congolensis* and dermatophytes has been reported in several studies (20, 21). Although mites such as *Chorioptes* spp. have been identified as a cause of dermatitis in cattle, no mites could be demonstrated in the lesions in the present study.

The results of this study confirm the aetiology of the condition called pododermatitis in Kerala to be *D. congolensis*. This is the first authentic report of the occurrence of dermatitis caused by dermatophilosis among cattle in Kerala. However, it has been reported recently in buffaloes, horses, goats, a dog and a human (22). The hot and humid climate, persistently moist conditions in cattle sheds, the presence of biting flies, and immunosuppression due to the stress associated with pregnancy and lactation may have resulted in an increased incidence of dermatophilosis among dairy cattle. The widespread occurrence of dermatophilosis among cattle in Kerala highlights the need for accurate and early diagnosis, proper treatment and control of the condition in order to improve the productivity of the livestock.

Acknowledgements

The authors are grateful to the Department of Animal Husbandry, Kerala, for the financial assistance provided, and to the Dean, College of Veterinary and Animal Sciences, Mannuthy, for the facilities provided.

Dermatophilus congolensis isolé à partir de lésions podales cutanées chez des bovins de l'état du Kérala, Inde

P.V. Tresamol, M.R. Saseendranath, H. Subramanian, U.N. Pillai, M. Mini & S. Ajithkumar

Résumé

Les auteurs présentent les résultats d'une étude visant à identifier les agents étiologiques associés à une dermatite podale particulière, dénommée localement pododermatite, affectant les vaches laitières de l'état du Kérala en Inde. Des croûtes et raclages cutanés collectés en conditions d'asepsie à partir de 82 vaches présentant une dermatite naturelle sur la partie inférieure de leurs membres ont été examinés au microscope et soumis à une culture bactérienne et fongique. L'examen au microscope des raclages cutanés dans une solution à 10 % d'hydroxyde de potassium a permis d'observer la présence de spores et de champignons dans des touffes de poils de deux des échantillons examinés ; en revanche, il n'a été observé aucun acarien ni d'autre parasite. Des dermatophytes des espèces suivantes ont été isolés et cultivés à partir de cinq des échantillons analysés, comme suit : *Trichophyton mentagrophytes* dans deux des échantillons et *T. verrucosum*, *Epidermophyton floccosum* et *Microsporum nanum* dans un échantillon chacun. L'examen au microscope de préparations colorées au Giemsa

et au Gram à partir de grattages des croûtes lésionnelles provenant de 72 cas a mis en évidence un organisme à la morphologie caractéristique, septé, présentant des ramifications filamenteuses gram-positives constituées de plusieurs rangées de coques sphériques ou ovoïdes agencées en « rails de chemin de fer » évocatrices de *Dermatophilus congolensis*. La culture en présence de dioxyde de carbone à 10 % sur gélose de sang ovin à partir des matériels des croûtes a permis d'obtenir des colonies bêta-hémolytiques caractéristiques de *D. congolensis* dans 75 échantillons. L'identification des isolats a été confirmée par l'observation macroscopique et microscopique de la morphologie caractéristique de l'organisme et par biochimie. Cette étude confirme la présence de la dermatophilose due à *D. congolensis* chez les bovins dans l'état du Kérala.

Mots-clés

Bovin – *Dermatophilus congolensis* – Dermatose de la partie inférieure des membres – Inde – Kérala – Pododermatite.



Identificación de *Dermatophilus congolensis* en ganado vacuno de Kerala (India) afectado de dermatitis de las patas traseras

P.V. Tresamol, M.R. Saseendranath, H. Subramanian, U.N. Pillai, M. Mini & S. Ajithkumar

Resumen

Los autores describen un estudio encaminado a determinar los agentes etiológicos de un tipo particular de dermatitis de las patas traseras, denominado localmente pododermatitis, que afectaba al ganado lechero de Kerala. Tras recoger en condiciones de asepsia costras y raspados de 82 animales naturalmente afectados por la enfermedad, se sometieron esas muestras a observación directa por microscopio y a cultivo bacteriano y micológico. El examen microscópico de los raspados de piel con hidróxido de potasio al 10% reveló la presencia de esporas fúngicas en los tallos pilosos de solo dos muestras, sin rastro alguno de ácaros u otros parásitos. Solo hubo cinco muestras cuyo cultivo micológico deparase dermatofitos, identificados como *Trichophyton mentagrophytes* en dos de ellas y como *T. verrucosum*, *Epidermophyton floccosum* y *Microsporum nanum* en cada una de las tres restantes. El examen microscópico de frotis de costras de las lesiones de 72 casos, con tinciones giemsa y gram, reveló la presencia de unos característicos filamentos septados ramificados gram-positivos con múltiples cadenas de cocos de forma entre esférica y ovoide y el típico aspecto que da en llamarse 'vía de tranvía', signo que apunta a *Dermatophilus congolensis*. El cultivo de las muestras de costras en un medio de agar sangre (de oveja) en presencia de un 10% de dióxido de carbono deparó las típicas colonias beta hemolíticas de *D. congolensis* en 75 muestras. La morfología macroscópica y microscópica de las colonias y los resultados de las pruebas bioquímicas corroboraron después la adscripción a esa especie de los organismos aislados. El estudio confirmó pues la presencia de dermatofilia causada por *D. congolensis* en el ganado vacuno de Kerala.

Palabras clave

Dermatophilus congolensis – Dermatitis de las patas traseras – Ganado vacuno – India – Kerala – Pododermatitis.



References

1. Awad W.S., Nadra-Elwgoud Abdou M.I. & El-Sayed A.A. (2008). – Diagnosis and treatment of bovine, ovine and equine dermatophilosis. *J. Appl. Sci. Res.*, **4** (4), 367–374.
2. Kahn C.M. (2005). – Dermatophilosis introduction. In *The Merck veterinary manual*, 8th Ed. (C.M. Kahn & S. Line, eds). Merck & Co., New Jersey, 690–692.
3. Ambrose N.C., Lloyd D. & Mallard J.C. (1999). – Immune responses to *Dermatophilus congolensis* infections. *Parasitol. Today*, **15** (7), 295–300.
4. Quinn P.J., Carter M.E., Markey B.K. & Carter G.R. (1994). – Clinical veterinary microbiology. Wolfe Publishing, United States of America, 648 pp.
5. Haalstra R.T. (1965). – Isolation of *Dermatophilus congolensis* from skin lesions in the diagnosis of streptothricosis. *Vet. Rec.* **77**, 824–834.
6. Cowan S.T. (1974). – Cowan and Steel's manual for identification of medical bacteria, 2nd Ed. Cambridge University Press, New York, 416 pp.
7. Pal M. (1995). – Prevalence in India of *Dermatophilus congolensis* infection in clinical specimens from animals and humans. *Rev. Sci. Tech. Off. Int. Epiz.*, **14** (3), 857–863.
8. Abu-Samra M.T. (1978). – Morphological, cultural and biochemical characteristics of *Dermatophilus congolensis*. *Zentralbl. Veterinärmed., B*, **25** (8), 668–688. doi:10.1111/j.1439-0450.1978.tb00776.x.
9. Hyslop N. (1980). – Dermatophilosis (streptothricosis) in animals and man. *Comp. Immunol. Microbiol. Infect. Dis.*, **2** (4), 389–404.
10. Searcy G.P. & Hulland T.J. (1968). – *Dermatophilus dermatitis* (streptothricosis) in Ontario. II. Laboratory findings. *Can. Vet. J.*, **9** (1), 16–21.
11. Samuel I., Tereke E., Wirtu G. & Kiros T. (1998). – Bacteriological study of Ethiopian isolates of *Dermatophilus congolensis*. *Trop. Anim. Hlth Prod.*, **30** (3), 145–147.
12. Hashemi Tabar G.R., Rad M. & Chavoshi M. (2004). – A survey on dermatophilosis in sheep in the north of Iran. *Iranian J. Vet. Res.*, **5**, 97–101.
13. Gordon M.A. (1964). – The genus *Dermatophilus*. *J. Bacteriol.*, **88** (2), 509–522.
14. El-Nageh M.M. (1971). – Comparison of strains of *Dermatophilus congolensis* Van Saceghem 1915 isolated from different species of animals. *Ann. Soc. Belge Méd. Trop.*, **51** (2), 239–246.
15. Kwanashie C.N., Addo P.B. & Saidu S.N.A. (1989). – Mixed infection of a cow with *D. congolensis* and *T. mentagrophytes*. *Trop. Vet.*, **7**, 42–44.
16. Mannan M.A., Khan M.S.R., Rahman M.M., Begum F. & Uddin M.Z. (2009). – Isolation and identification of dermatophilus bacteria from the skin lesions of cattle. *Bangladesh J. Vet. Med.* **7** (2), 342–347.
17. Nath B.D., Ahasa M.S., Rehman M.S. & Haque A.K.M.F. (2010). – Prevalence and therapeutic management of bovine dermatophilosis. *Bangladesh Res. Pub. J.*, **4** (3), 198–207.
18. Pier A.C., Neal F.C. & Cystewski S.J. (1963). – Cutaneous streptothricosis in Iowa cattle. *J. Am. Vet. Med. Assoc.*, **142**, 995–1000.
19. Shaibu S.J., Kazeem H.M., Abdullahi U.S. & Fatihu M.Y. (2011). – Phenotypic and genotypic characterisation of isolates of *Dermatophilus congolensis* from cattle, sheep and goats in Jos, Nigeria. *Afr. J. Microbiol. Res.*, **5** (5), 467–474.
20. Abdel-Halim M.M., El-Fayomy M.M., El-Sayed M.M. & Abdel-Samee A.A. (1995). – Dermatophilosis in farm animals in Egypt. Clinical studies, diagnosis and treatment. *J. Egypt. Vet. Med. Assoc.*, **55** (1&2), 325–337.
21. Kaminski G.W. & Suter I.I. (1976). – Human infection with *Dermatophilus congolensis*. *Med. J. Aust.*, **1** (13), 443–447.
22. Tresamol P.V. & Saseendranath M.R. (2014). – Dermatophilosis: an emerging skin disease of domestic animals in Kerala. In *Proc. 26th Kerala Science Congress* (V.N.R. Pillai, ed.), 28–31 January, Wayanad, Kerala, 694–696.